群馬県立自然史博物館研究報告(25)：1－18,2021
Bull.Gunma Mus.Natu.Hist.(25)：1－18,2021

Original Article

Myology and osteology of the Whooper Swan *Cygnus cygnus* (Aves: Anatidae) Part 3. Muscles attached to the pelvis, femur, tibiotarsus, tarsometatarsus and phalanx

MATSUOKA Hiroshige[1,2] and SEOKA Riko[1,3]
[1]*Department of Geology and Mineralogy, Graduate School of Science, Kyoto University, Kyoto 606-8502, Japan.*
[2]*maca@kueps.kyoto-u.ac.jp*
[3]*seoka.riko.52m@st.kyoto-u.ac.jp*

Abstract: This paper clarifies the myological system of the pelvis and hind limb osteology of Whooper Swan *Cygnus cygnus* (Anatidae). All major muscles and ligaments were examined to determine the attachments (origin and insertion) on the bones and illustrated in detail. Totally, 48 muscles are identified: 18 muscles around the pelvis and femur, 7 muscles arising from the caudal portion of the pelvis and affecting tail movement, 16 crus muscles that appear as tendons at the ankle, 1 deep muscle in the crus that does not cross the knee/ankle joint, and 6 muscles arising from the tarsometatarus. The authors did not find M. lumbriealis in the examined specimen and currently conclude that M. lumbiralis is absent in *Cygnus*. The preserved specimen of whooper swan (GMNH-VA-04-02 of Gunma Museum of Natural History) had already been used for anatomical examination twice, first for the pectoral and wing bones and then the head. This paper is the third and last of this series.

Key Words: Anatidae, Whooper swan, *Cygnus cygnus*, myology, osteology, leg muscles

INTRODUCTION

To reconstruct the muscular system on the fossilized bones of extinct animals, we need detailed information on the muscle-bone connection of the related extant species. For this purpose, we already have some anatomical descriptions, such as Suzuki's (2011) work on crocodile and Yasuda's (2011) book on the anatomy of domestic fowl. However, the information we have on the osteology of birds is still limited, as the literatures on myology usually lack the detailed description and good illustration on the osteology where the muscle attaches on. For example, even the widely cited Ghetie (1976) and comprehensive book on the "Avian Myology" (George and Berger, 1966), the information on the detailed place and shape of the muscular attachment on bone is poor. Yasuda (2011) showed some illustrated guide of muscular attachment on bone about domestic fowl, but lacks the text, and in addition because he used highly unique terminology then very difficult to refer. Examples of work on the myology of waterfowl, e. g. Clifton et al. (2018), show and analyze the relative volume of muscles, but have not described the osteology in detail.

So, to answer the paleontologists' desire, the senior author of this paper HM have conducted the works visualizing the attachment positions of muscles on bones by using a pickled specimen of whooper swan (*Cygnus cygnus*) (GMNH-VA-04-02 of Gunma Museum of Natural History). The first report was on the pectoral girdle (Matsuoka and Hasegawa, 2007) and the second was on head (Matsuoka et al., 2008). As the third and final report using this specimen, this paper reports on the muscles of pelvic and hind limb region of *Cygnus cygnus*. (Because the tendinous system of the foot is horribly complicated, it took much time to start work on it before meeting a good dissection worker RS.) Swans are a large waterbird characteristic for the foot propelled flouting with big and webbed feet. Authors expect this report will be useful to find the relations of bone morphology and muscular system (motion) of large, volant, and foot propelled waterbirds.

See Matsuoka and Hasegawa (2007) for the information on the bird material used here. The name of muscles follows Baumel (1979), and the Japanese names follows Japanese Association of Veterinary Anatomists (eds., 1998). In the case George and Berger (1966) use another name from Baumel, the synonym(s) are noted.

RESULT

Totally 48 muscles are identified on dissected specimen of *Cygnus cygnus* in this study (Tab. 1). The process of dissection of muscles are illustrated on figures 1-7, and the measured drawing of pelvis (Fig. 8), the hind limb skeletal element (Fig, 9), and the guide to osteology of these bones (Fig. 10, Tab. 2) summarize this study. Illustrations on this paper are the most complete guide to the hind limb osteology of anatid bird, we believe. The 48 muscles are classified to: 18 muscles around pelvis and femur, 7 muscles arising from the caudal pelvis to concern the action of tail, 16 crus muscles appear as tendon at ankle, 1 deep muscle in crus which does not cross knee/ankle joints, and 6 muscles arising from tarsometatarsus.

18 muscles around pelvis and femur (PF1-PF18) (Figs. 1-4)

1. M. iliotibialis cranialis

前腸脛骨筋
(M. sartorius, Extensor iliotibialis anterior)
M. iliotib. cran., or PF1 in figures.

M. iliotibialis cranialisis is a long muscle in the most anterior position among pelvic muscles. M. iliotibialis cranialisis arises by an aponeurosis from the curved line in the anterior 20 mm of dorsal surface of the ala preacetabularis illi of pelvis (Fig. 10-point 8) and inserts by short tendinous fibers on the anteromedial surface of the patellar ligament (Fig. 3).

2. M. iliotibialis lateralis

外側腸脛骨筋
(M. iliotibialis, Extensor iliotibialis lateralis)
M. iliotib. lat., or PF2 in figures.

M. iliotibialis lateralis is the most superficial muscle on the lateral surface of the thigh. This muscle is totally flat and only at its central portion a sheet-like belly exists. M. iliotibialis lateralis arises by an aponeurosis from the posterior 80 mm of the line lateral to the median dorsal ridge of anterior ilium, with the anterior point being just posterior to the posterior end of the origin of M. iliotibialis cranialisis and posterior end at about the position of antitrochanter (Fig. 10- point 9). The distal one-third is fused with the subjacent M. femorotibialis lateralis + medialis (Fig. 2).

Submitted：December 10, 2020; accepted：February 3, 2021

3. M. iliofibularis
腸腓骨筋
(M. biceps femoris, Extensor iliofibularis)
M. iliofib., or PF3 in figures.

M. iliofibularis is superficial in most part but the insertion penetrates the interstice of crus muscles. The muscle arises by fleshy fibers from the anterior half of the posterior iliac crest, the area just dorsal to the foramen ilioischiadicum (Fig. 10- point 16). To the insertion (Fig. 10- point 56) the belly gives rise to a strong tendon which passes through the ligamentous "biceps loop" and inserts on a tubercle on the posterior surface of fibula.

4. M. flexor cruris lateralis pars pelvica
外側下腿屈筋骨盤部
(M. semitendinosus)
M. flex. cru. lat. pelv., or PF4 in figures.

M. flexor cruris lateralis pars pelvica is the largest superficial muscle in the lower half of the body of *Cygnus cygnus*. Posterior to the m. iliofibularis, the origin of m. flexor cruris lateralis pars pelvica extends caudally to the proc. transversus of two or three vertebrae caudares liberae, and the width of origin occupy nearly the two-fifth of the total craniocaudal length (sum of the width for each muscles) of pelvic muscular system. The muscle arises by fleshy fibers from the posterior half of the posterior iliac crest (Fig. 10- point 17) and by tendinous fibers from the proc. transversus of vertebrae caudares liberae. The insertion fuses to M. flexor cruris medialis and by passing the interstice between M. gastrocnemius pars medialis and other tibial muscles it stops on the 15 mm long tuberosity being lateral surface of the proximal tibiotarsus (Fig. 10- point 72).

5. M. iliotrochantericus caudalis
後腸骨転子筋
(M. iliotrochantericus posterior, Gluteus profundus)
M. iliotroch. caud., or PF5 in figures.

M. iliotrochantericus caudalis, appears after M. iliotibialis is removed, is a massive muscle lying in the anterior iliac fossa. M. iliotrochantericus caudalis arises by fleshy fibers from the dorsal surface of nearly entire ala preacetabularis illi (Fig. 10- point 10). The most posterior fibers of the muscle arise anterodorsal to the acetabulum. Between the bone and this muscle, the network of blood vessels is inserted, and the some of the vessels leave impression of themselves on the bone surface (Fig. 2). M. iliotrochantericus caudalis inserts by a wide and dense tendon on a curved deep depression on the lateral surface of femur just distal to the trochanter (Fig. 10- point 26).

6. M. iliofemoralis externus
外腸骨大腿筋
(M. Gluteus Medius et Minimus)
M. iliofem. ext., or PF6 in figures.

M. iliofemoralis externus is a short muscle situated at the posterior next of M. iliotrochantericus caudalis. The origin (Fig. 10- point 13) is on the iliac crest dorsal to the acetabulum and the muscle arises by fleshy fibers. Its fibers pass over the trochanter to insert by a small tendon on the lateral surface of the proximal end of femur, just proximal to the insertion of M. ischiofemoralis (Fig. 10- point 32), with an anchor attaching on the proximolateral edge of femur (Fig. 10- point 29).

7. M. iliotrochantericus cranialis
前腸骨転子筋
(M. iliotrochantcricus anterior)
M. iliotroch. cran., or PF7 in figures.

In contrast to the massive M. iliotrochantericus caudalis, M. i. cranialis, which appears after M. i. caudalis is removed, is a flat and small muscle. The origin of M. iliotrochantericus cranialis (Fig. 10- point 11) is by tendinous in cranial portion and by fleshy in caudal portion. The cranial portion arises from the ventrolateral edge of the ilium. The origin turns to fleshy belly to attach on the marginal area of ilium in the posterior portion. M. iliotrochantericus cranialis inserts by tendinous on the anterolateral surface of femur, beginning 10 mm distal to the trochanter (Fig. 10- point 27).

8. M. iliotrochantericus medius
中腸骨転子筋
M. iliotroch. med., or PF8 in figures.

M. iliotrochantericus medius is a small fleshy muscle arising from the ventral edge of the ilium just anterior to the acetabulum and posterior to the origin of M. iliotrochantericus cranialis (Fig. 10- point 12). The belly passes outward to insert on the femur. The insertion of M. iliotrochantericus medius is the rough surface being on the anterior surface of the neck of femur (Fig. 10- point 42).

9. M. femorotibialis externus
外大腿脛骨筋
(Vastus lateralis)
M. fem.tib. ext., or PF9 in figures.

M. femorotibialis externus of *Cygnus cygnus* is almost fused to much larger M. femorotibialis medialis. The origin is the area of point 34 of Fig. 10. The insertion is fused to PF2 and PF10, and then partly on the margin of patellar ligament and partly on the proximal surface of patellar (Figs. 2 and 3).

10. M. femorotibialis medialis
内側大腿脛骨筋
(M. femorotibialis medius, Vastus medialis)
M. fem.tib. med., or PF10 in figures.

M. femorotibialis medius and its posterolateral next muscle M. femorotibialis externus (listed above: PF9) are fused and form a large muscular mass at the anterior and lateral neighborhood of femur. They are fused along their contiguous borders and only at the distal part of a membrane shows their original territories. M. femorotibialis medialis arises by tendinous fibers from the trochanteric ridge, forming a line on femur (Fig. 10- point 44), and by fleshy fibers widely from the anterolateral surface of the shaft of the femur (Fig. 10- point 33), both anteromedial and posterolateral to the trochanteric ridge, throughout nearly its entire length. M. femorotibialis externus arises by fleshy fibers from the distal area of lateral surface of the shaft (Fig. 10- point 34). M. femorotibialis medius + M. f. externus form dense aponeuroses to the insertion on the patellar ligament. The fleshy belly of M. femorotibialis medialis inserts on the proximal border of patella (Figs. 2 and 3).

11. M. femorotibialis intermedius
中間大腿脛骨筋
(M. femorotibialis internus)
M. fem.tib. int., or PF11 in figures.

M. femorotibialis intermedius lies on the medial surface of the thigh, lying between the M. femorotibialis medialis and insertion of M. puboischiofemoralis. The muscle arises by fleshy fibers from the medial surface of the shaft of femur (Fig. 10- point 43), and then inserts by a tendon on the anteromedial corner at the base of crista cnemialis cranialis of tibiotarsus (Fig. 10- point 60).

12. M. ischiofemoralis
座骨大腿筋
M. ischiofem. or PF12 in figures.

M. ischiofemoralis appears widely in the lateral surface of posterior pelvis after M. iliofibularis and M. flexor cruris lateralis pars pelvica are removed. This wide muscle arises from nearly the entire lateral surface of the ischium beginning at about middle of foramen ilioischiadicum and extending to the caudal end of the bone (Fig. 10- point 18). M. ischiofemoralis lies deep to M. iliofibularis and M. flexor cruris lateralis pars pelvica and the upper margin of its belly adjoins the origins of superficial two muscles. The lower margin of the belly of M. ischiofemoralis fuses to the upper margin of M. caudofemoralis. The belly of M. ischiofemoralis + M. caudofemoralis passes forward and inserts by a strong tendon on the linea intermuscularis caudalis of femur (Fig. 10- point 46).

13. M. caudofemoralis
尾大腿筋
(M. piriformis)
M. caudofem. or PF13 in figures.

M. caudofemoralis is one of the muscles concerned in the action of tail, then should be categorized next, but is listed here

Table 1. The list of 48 pelvic and leg-foot muscles of Whooper Swan *Cygnus cygnus*.

18 muscles around pelvis and femur			
PF1	M. iliotib. cran.	M. iliotibialis cranialis	前腸脛骨筋
PF2	M. iliotib. lat.	M. iliotibialis lateralis	外側腸脛骨筋
PF3	M. iliofib.	M. iliofibularis	腸腓骨筋
PF4	M. flex. cru. lat. pelv.	M. flexor cruris lateralis pars pelvica	外側下腿屈筋骨盤部
PF5	M. iliotroch. caud.	M. iliotrochantericus caudalis	後腸骨転子筋
PF6	M. iliofem. ext.	M. iliofemoralis externus	外腸骨大腿筋
PF7	M. iliotroch. cran.	M. iliotrochantericus cranialis	前腸骨転子筋
PF8	M. iliotroch. med.	M. iliotrochantericus medius	中腸骨転子筋
PF9	M. fem.tib. ext.	M. femorotibialis externus	外大腿脛骨筋
PF10	M. fem.tib. med.	M. femorotibialis medialis	内側大腿脛骨筋
PF11	M. fem.tib. int.	M. femorotibialis intermedius	中間大腿脛骨筋
PF12	M. ischiofem.	M. ischiofemoralis	座骨大腿筋
PF13	M. caudofem.	M. caudofcmoralis	尾大腿筋
PF14	M. flex. cru. med.	M. flexor cruris medialis	内側下腿屈筋
PF15	M. pub.isch.fem. lat.	M. puboischiofemoralis pars lateralis	恥座大腿筋外側部
	M. pub.isch.fem. med.	M. puboischiofemoralis pars medialis	同内側部
PF16	M. obt. lat.	M. obturatorius lateralis	外側閉鎖筋
PF17	M. obt. med.	M. obturatorius medialis	内側閉鎖筋
PF18	M. amb.	M. ambiens	迂回筋
7 muscles arising from the caudal pelvis to concern the action of tail			
	M. lev. caud. vert.	M. levator caudae pars vertebralis	尾挙筋椎骨部
	M. lat. caud.	M. lateralis caudae	尾外側筋
	M. lev. caud. rectr.	M. levator caudae pars rectricalis	尾挙筋尾羽部
	M. pubocaud. ext.	M. pubocaudalis externus	外恥骨尾筋
	M. pubocaud. int.	M. pubocaudalis internus	内恥骨尾筋
	M. trans cloac.	M. transversus cloacae	排泄腔横筋
	M. dep. caud.	M. depressor caudae	尾下制筋
16 crus muscles appear as tendon at ankle			
T1	M. ext. dig. long.	M. extensor digitorum longus	長趾伸筋
T2	M. tib. cran.	M. tibialis cranialis	前脛骨筋
T3	M. fib. brev.	M. fibularis brevis	短腓骨筋
T4	M. fib. long.	M. fibularis longus	長腓骨筋
T5	M. flex. p. et p. dig. III	M. flexor perforans et perforatus digiti III	第三趾貫通および有孔屈筋
T6	M. flex. p. et p. dig. II	M. flexor perforans et perforatus digiti II	第二趾貫通および有孔屈筋
T7	M. gastric. lat.	M. gastrocnemius pars lateralis	腓腹筋外側部
T8	M. flex. perf. dig. IV	M. flexor perforatus digiti IV	第四趾有孔屈筋
T9	M. flex. perf. dig. III acs.	M. flexor perforatus digiti III – the accessory	第三趾有孔屈筋（その付属部）
T10	M. flex. perf. dig. III main	M. flexor perforatus digiti III – the main	第三趾有孔屈筋（その主部）
T11	M. flex. hal. long.	M. flexor hallucis longus	長母趾屈筋
T12	M. flex. perf. dig. II	M. flexor perforatus digiti II	第二趾有孔屈筋
T13	M. flex. dig. long.	M. flexor digitorum longus	長趾屈筋
T14	M. gastric. med.	M. gastrocnemius pars medialis	腓腹筋内側部
T15	M. plant.	M. plantaris	足底筋
T16	M. gastric. intermed.	M. gastrocnemius pars intermedia	腓腹筋中間部
1 deep muscle in crus doesn't cross knee/ankle joints			
	M. pop.	M. popliteus	膝窩筋
6 muscles arising from tarsometatarsus			
Ft1	M. ext. hal. long.	M. extensor hallucis longus	長母趾伸筋
Ft2	M. abd. dig. II	M. abductor digiti II	第二趾外転筋
Ft3	M. ext. dig. III	M. extensor proprius digiti III	第三趾固有伸筋
Ft4	M. ext. brav. dig. IV	M. extensor brevis digiti IV	第四趾短伸筋
Ft5	M. abd. dig. IV	M. abductor digiti IV	第四趾外転筋
Ft6	M. ad. dig. II	M. adductor digiti II	第二趾内転筋

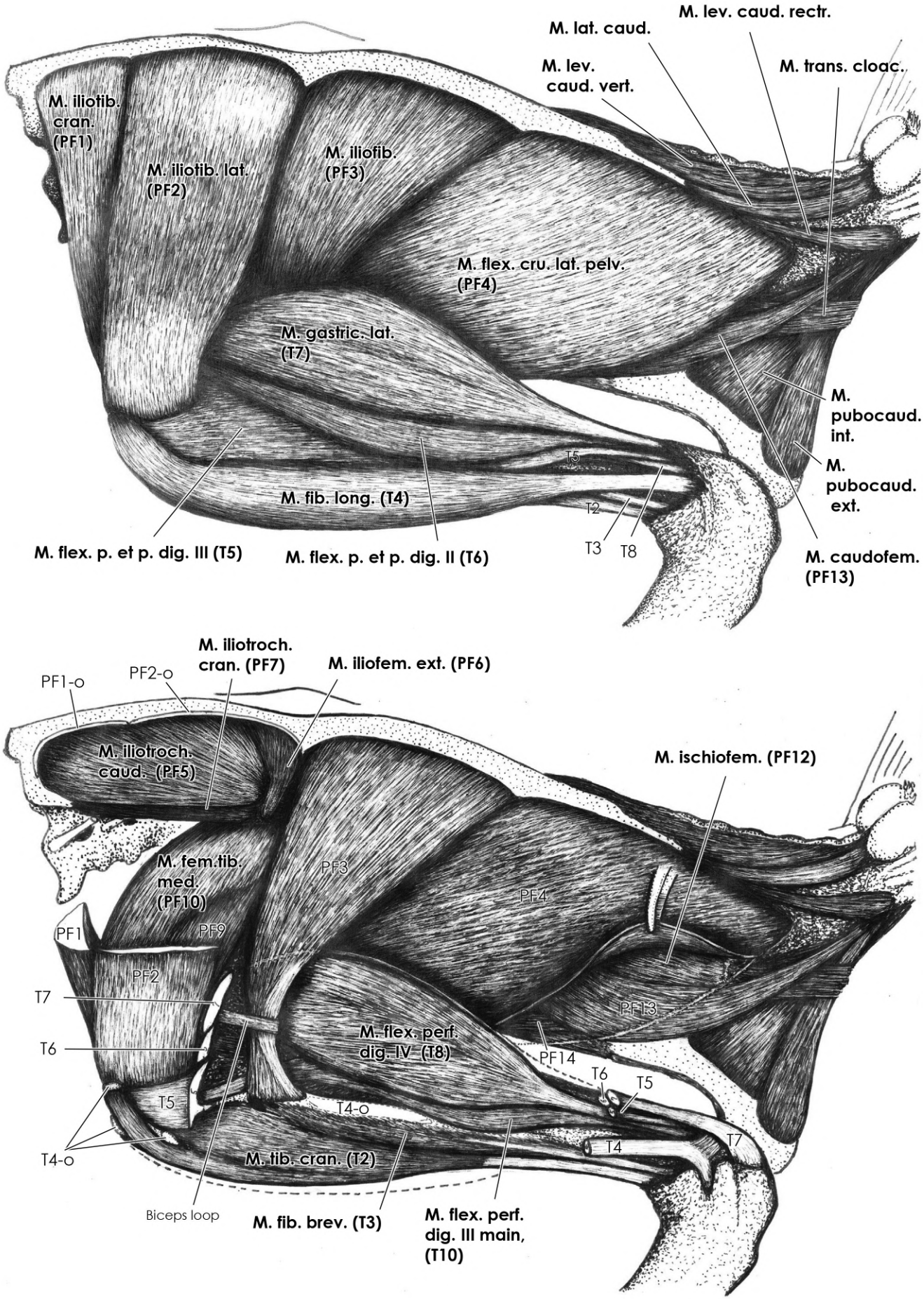

Figure 1. The lateral view of the muscles around pelvis, femur and crus of Whooper Swan *Cygnus cygnus* (1). The superficial (top) and a shallow (bottom) layers. See Table 1 for the muscle name abbreviations. Abbreviation o means origin. Not a measured drawing.

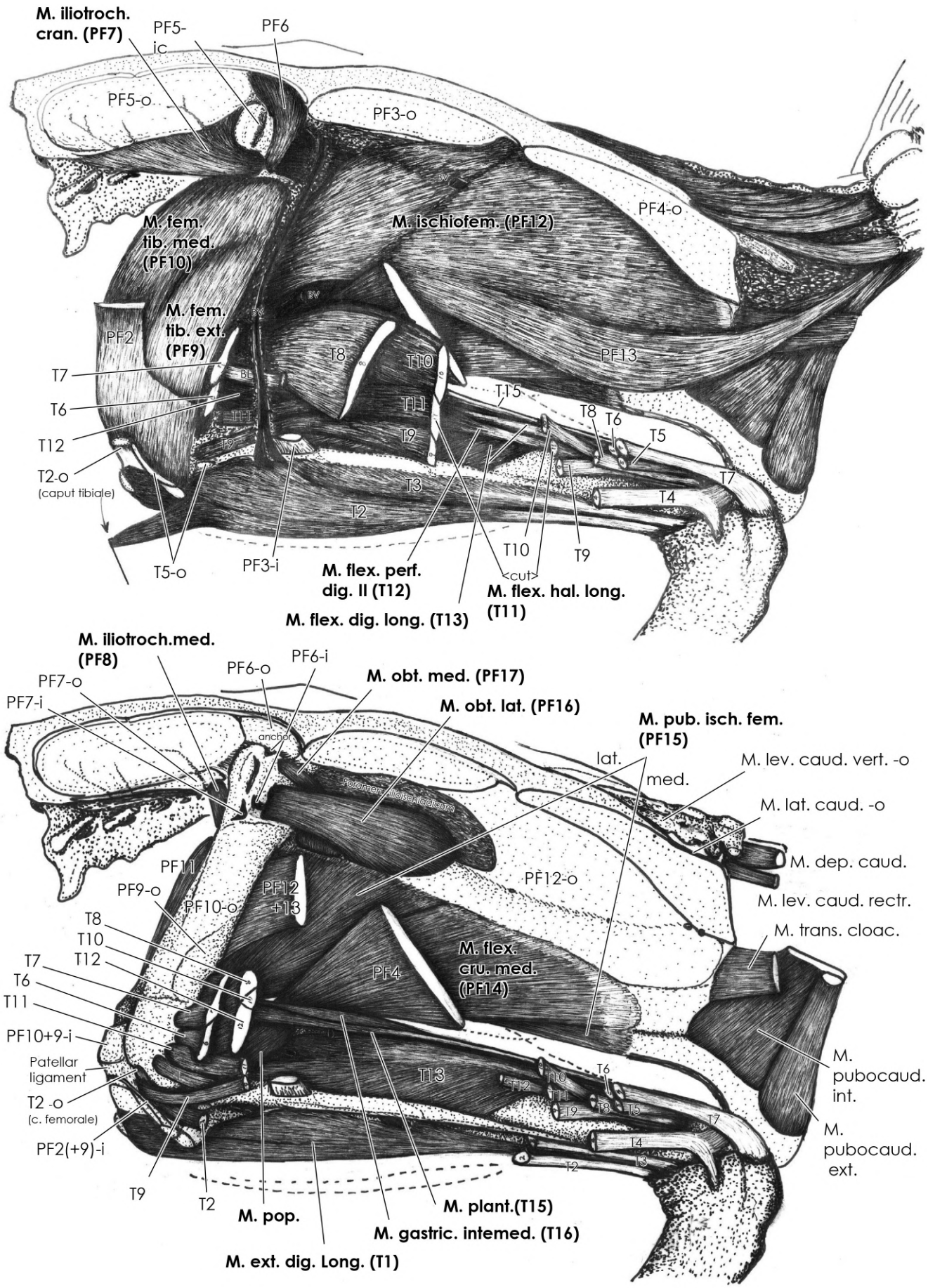

Figure 2. The lateral view of the muscles around pelvis, femur and crus of Whooper Swan *Cygnus cygnus* (2). A deep (top) and the deeper (bottom) layers. See Table 1 for the muscle name abbreviations. Other abbreviations mean: BL,biceps loop; BV, blood vessel; o, origin. Not a measured drawing.

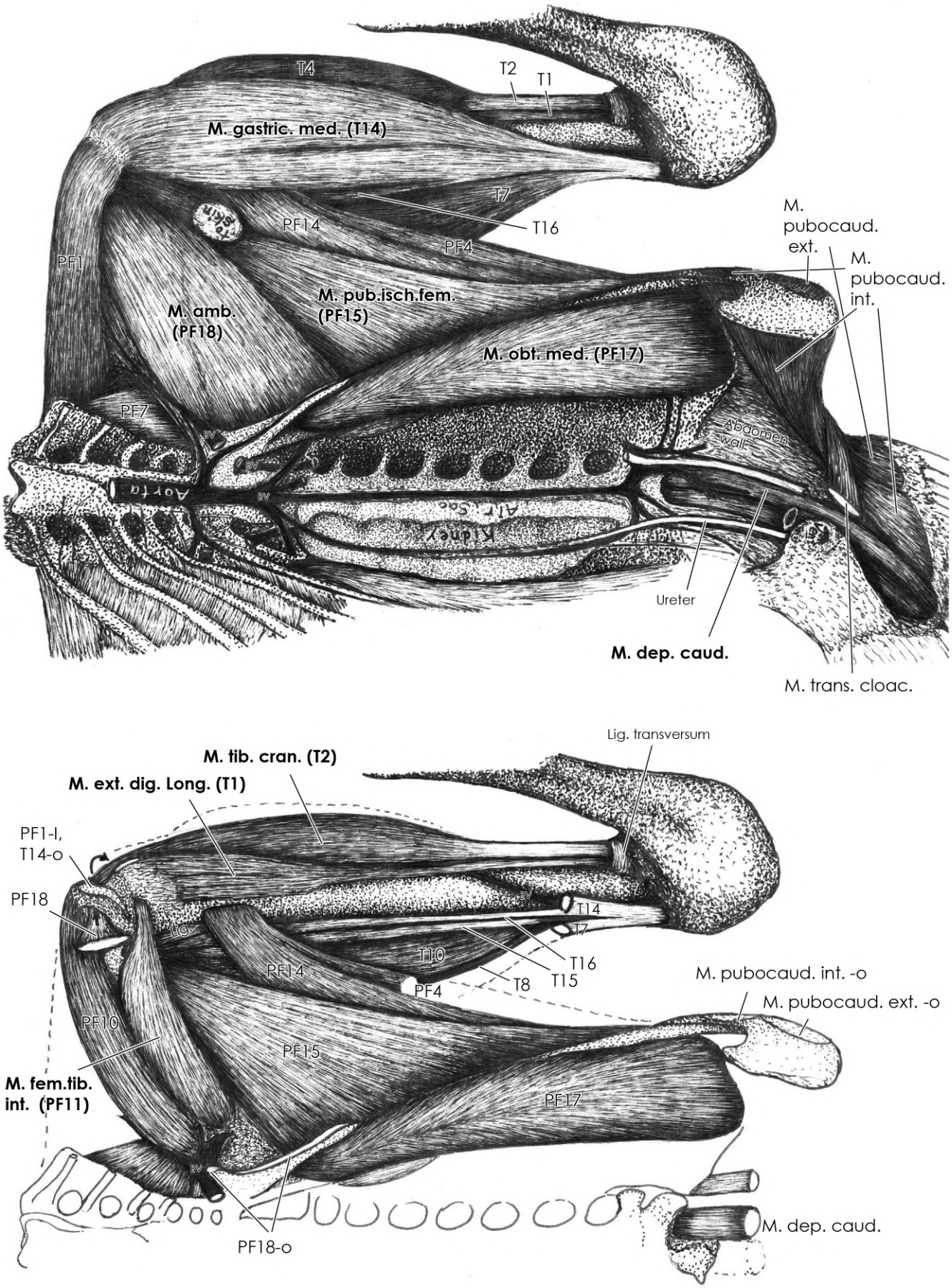

Figure 3. The medial (ventral, visceral) view of the muscles around pelvis, femur and crus of Whooper Swan *Cygnus cygnus*.
The superficial (top) and a deep (bottom) layers. A skin muscle arises from the surface of some muscles and inserts to skin at the medial portion of knee joint. See Table 1 for the muscle name abbreviations. Other abbreviations mean: BV, blood vessel; i, insertion; o, origin. Not a measured drawing.

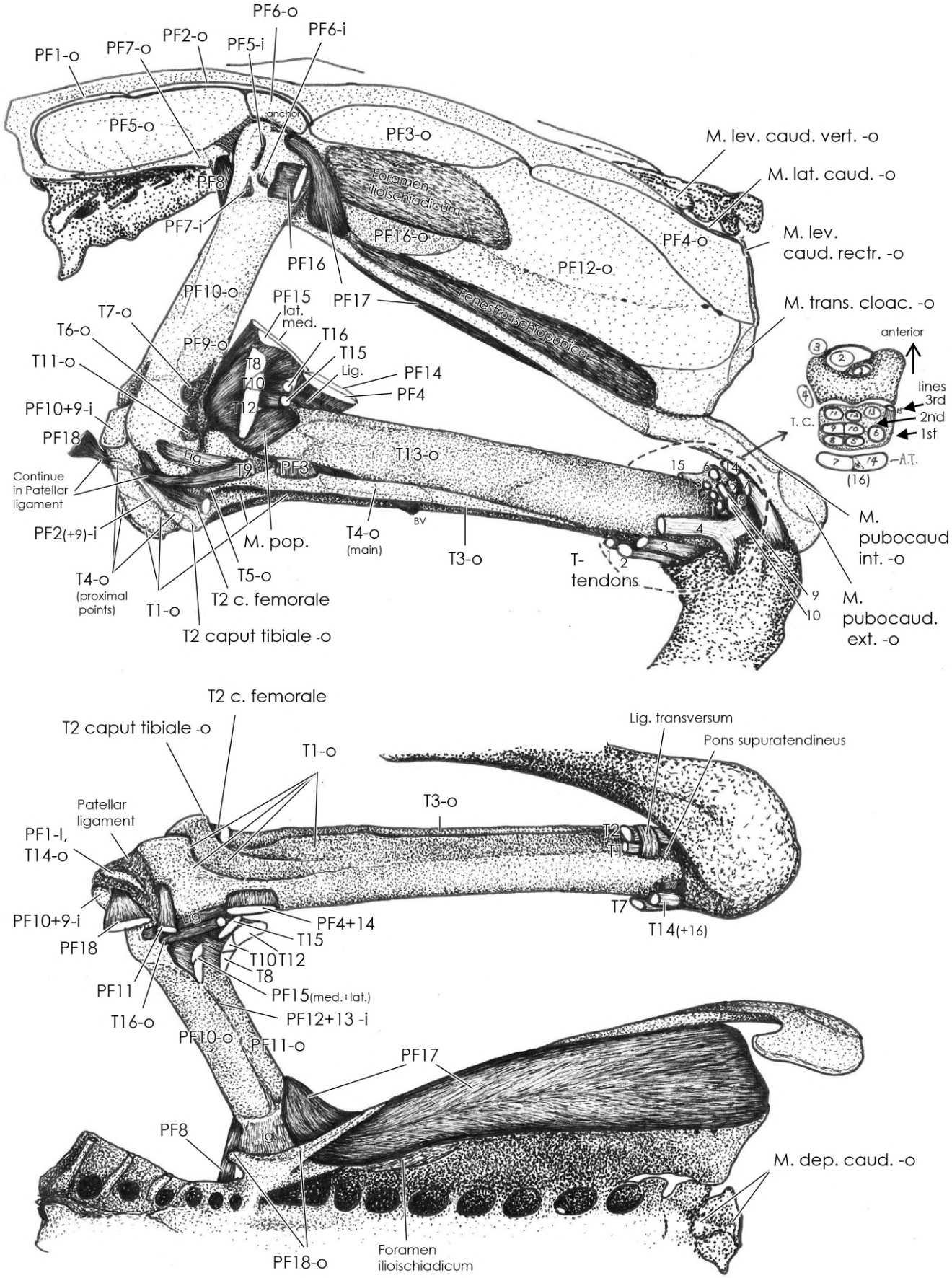

Figure 4. The articulated pelvic and hind limb skeletal elements of Whooper Swan *Cygnus cygnus*, with some deepest muscles and cut muscle terminations. The lateral (top) and medial (ventral) views. See Table 1 for the muscle name abbreviations. Other abbreviations mean: A.T., Tendo Achillis; BV, blood vessel; i, insertion; o, origin; T.C., tibial cartilage. Not a measured drawing.

because this muscle is fused to M. ischiofemoralis. M. caudofemoralis is superficial for its caudal terminating portion and the most, cranial, potion is deep to M. iliofibularis and M. flexor cruris lateralis pars pelvica. The anterior half of the muscle is fused to the lower margin of M. ischiofemoralis. M. caudofemoralis arises by fleshy fibers from the ventral surface of the plane formed by the bases of rectrices. The long, strap-like belly penetrates the interstice between superficial M. flexor cruris lateralis pars pelvica and deeper M. flexor cruris medialis and passes forward alongside the upper margin of M. flexor cruris medialis. The insertion of M. caudofemoralis (Fig. 10- point 46) is fused to M. ischiofemoralis.

14. M. flexor cruris medialis

内側下腿屈筋

(M. semimembranosus, Flexor cruris medialis)

M. flex. cru. med., or PF14 in figures.

M. flexor cruris medialis is the deepest except the posterior portion of M. puboischiofemoralis pars medialis in the posterior pelvic muscles. Deep to the M. flexor cruris lateralis pars pelvica and M. caudofemoralis, M. flexor cruris medialis arises by an aponeurosis from the lateral surface of the upper margin of fenestra ischiopubica (Fig. 10- point 19). The belly passes parallel to the distal portion of M. flexor cruris lateralis pars pelvica (PF4) and fuses to it for insertion. The belly of fused M. flexor cruris medialis and M. flexor cruris lateralis pars pelvica passes the interstice between M. gastrocnemius pars medialis and other tibial muscles and inserts on the tuberosity on the lateral surface of the proximal tibiotarsus (Fig. 10- point 72).

15. M. puboischiofemoralis pars lateralis, pars medialis

恥座大腿筋外側部，同内側部

(Adductor longus et brevis, Adductor superficialis et profundus)

By parts, M. pub.isch.fem. lat., or PF15 lat., and M. pub.isch.fem. med., or PF15 med., in figures.

M. puboischiofemoralis pars lateralis is a relatively thick fleshy muscle and locates cranial to pars medialis. The pars medialis is a wide and thin triangular shaped muscle and locates caudal to pars lateralis, and then this muscle is widely visible in the visceral view of skinned thigh. Both parts arise by shared aponeurosis from the ventral margin of the ischium, just deeper to the origin of M. flexor cruris medialis (Fig. 10- point 20), and the aponeurosis passes over the ischiopubic membrane of fenestra ischiopubica. The bellies of two parts passes cranially and inserts on the lateral surface of the distal end of femur (Fig. 10- point 47).

16. M. obturatorius lateralis

外側閉鎖筋

(M. obturator externus)

M. obt. lat., or PF16 in figures.

M. obturatorius lateralis is the deepest muscle in the lateral side of posterior pelvis except the thin muscles (PF14 and PF15) arise from the lower margin of ischium. The muscle arises by fleshy fibers from the anterior ischium and the lower portion of the membrane fixing in the foramen ilioischiadicum (Figs. 2 and 4: the skeletal insertion is on the point 21 of Fig. 10). The belly passes cranially and inserts by wide tendon on the lateral surface of proximal end of femur (Fig. 10- point 31).

17. M. obturatorius medialis

内側閉鎖筋

(M. obturator internus)

M. obt. med., or PF17 in figures.

M. obturatorius medialis, a long and feather-shaped muscle hugging on the the medial surface of the fenestra ischiopubica is standing out in the medial (visceral) view of dissected thigh (after visceral organs are removed). The fleshy origin extends caudally, and the posterior tip of origin (Fig. 10- point 17) is at the end of the ischium. The fleshy belly converges to the middle of muscle, tapers cranially and turns to a stout tendon, and by passing the foramen obturatum (Fig. 10- point 15) the insertion appears to the lateral side of pelvis. The inserting thick tendon passes the back of M. ischiofemoralis and insertss on the posterolateral corner of the proximal end of femur (Fig. 10- point 30).

18. M. ambiens

迂回筋

M. amb., or PF18 in figures.

M. ambiens is a big flat muscle covering the inside of thigh widely. Anatomically, this is the most medial muscle of the thigh. The origin of M. ambiens is the ventral edge of the anterior portion of pubis (Fig. 10- point 1), of which the cranial termination is the tuberculum preacetabulare, and the muscle arises by tendon from the tip of tuberculum preacetabulare and by freshy fibers from the rest of origin. The fleshy belly tapers sharply to a small tendon at the position of distal end of the femur, and the tendon then inserts into the cartilaginous compartment in the patellar ligament and passes along the patella with a diagonal course from medial to lateral to reach and appear on the lateral surface of knee. The knee tendon of M. ambiens then continues downward to cross the lateral surface of the proximal end of fibula and shoots for the position deep to the inserting tendon of M. iliofibularis. The continues (distal) portion the tendon of M. ambiens fans out to fleshy belly again and gives rise to the head of T9 muscle. The performance of T9 muscle will be written in below.

7 muscles arising from the caudal pelvis to concern the action of tail

(Figs. 1-4)

1. M. levator caudae pars vertebralis

尾挙筋椎骨部

M. lev. caud. vert. in figures.

M. levator caudae arises by fleshy fibers from the dorsal plane of fused caudal vertebrae of synsacrum medial to the dorsoposterior margin of posterior ilium (Fig. 10- point 23). The bellies pass caudad lateral to the neural spines of some cranial free caudal vertebrae and the muscle inserts on the neural spines of posterior free caudal vertebrae and pygostyle.

2. M. lateralis caudae

尾外側筋

M. lat. caud. in figures.

M. lateralis caudae arises by fleshy fibers from the most dorsoposterior portion of the dorsal surface of posterior ilium, the area just laterocaudal to the origin of M. levator caudae (Fig. 10- point 24). Together with medially passing M. levator caudae, passes caudad and inserts on the posterior free caudal vertebrae and pygostyle.

3. M. levator caudae pars rectricalis

尾挙筋尾羽部

M. lev. caud. rectr. in figures.

M. levator caudae pars rectricalis is the string-like fleshy muscle locates ventral to M. lateralis caudae in the lateral view. The muscle arises partly from the transverse process of last fused caudal vertebra of synsacrum and mainly from the ventral side of the posterodorsal corner of ilium (Fig. 10- point 6). Inserts mainly on the lateral surface of the base of most lateral rectrix, and the fanning fibers cover the ventral surface of the tabular base of rectrices.

4. M. pubocaudalis externus

外恥骨尾筋

(A part of M. depressor caudae in George and Berger)

M. pubocaud. ext. in figures.

Arises by fleshy fibers widely from the lateral surface of the posterior portion of pubis, the area of its posterodorsal corner of boot-shaped termination (Fig. 10- point 5). Inserts on the lateral portion of the ventral surface of the tabular base of rectrices.

5. M. pubocaudalis internus

内恥骨尾筋

(A part of M. depressor caudae in George and Berger)

M. pubocaud. int. in figures.

M. pubocaudalis internus is much wider and deeper muscle to M. pubocaud. externus. Arises by partly (visceral side) an aponeurosis and partly (lateral side) fleshy fibers from the visceral surface of proc. terminalis ischii and dorsal margin of posterior pubis (Fig. 10- point 4). The posterior portion of origin is overlapped by that of M. pubocaud. externus. Inserts widely on the relatively medial portion of the ventral surface of the tabular base of rectrices.

6. M. transversus cloacae

排泄腔横筋

(M. transversoanalis)

M. trans. cloac. in figures.

This muscle bounds the body wall wrapping internal organs to the pelvis (skeleton). The band-like muscle arises from a portion of the caudal margin of ischium (Fig. 10- point 22). At about the middle of origin of this muscle, a tubercle projecting caudad is formed. The right and left M. transversus cloacae fuse in the midline of the body around cloacae, which is cut off in figures in this study.

7. M. depressor caudae

尾下制筋

(M. depressor coccygis)

M. dep. caud. in figures.

M. depressor caudae is the deepest muscle of the ventral tail. The muscle arises from the chevron tubercle of the last fused caudal vertebra and the first free caudal vertebra (Fig. 10- point 7) and inserts on the ventral margin of pygostyle.

16 crus muscles appear as tendon at ankle (T1-T16)

(Figs. 1-7. The relative positions of the belly and the tendon at ankle of each muscles are featured in Fig. 5)

1. M. extensor digitorum longus

長趾伸筋

M. ext. dig. long., or T1 in figures.

M. extensor digitorum longus is the deepest muscle in the anterior portion of tibiotarsus. The muscle arises widely from the anterior surface of proximal tibiotarsus (Fig. 10- point 53): by strong fivers from the lateral surface of crista cnemialis cranialis, by fleshy fibers from the anterior surface of sulcus intercristalis, lateral base of crista cnemialis lateralis with deep impression on bone, and the lateral portion of anterior shaft including crista fibularis. The belly tapers to a thick tendon in distal, and the tendon passes under the Ligamentum transversum together with the tendon of M. tibialis cranialis and then singly through the canal under the bony bridge (pons supuratendineus). The tendon crosses the anterior edge of the tibiotarsal-tarsometatarsal joint and continues its course along the anterior surface of the tarsometatarsus. The tendon fans out in the distal to totally four, at first branches to three and soon after the medial one branches to a folk. Four tendons go one each to digits II and IV, and two tendons to digit III. The tendons perform complicated branching and stoppings in the anterior surface of the foot skeleton (Fig. 6).

2. M. tibialis cranialis

前脛骨筋

(M. tibialis anterior)

M. tib. cran., or T2 in figures.

The belly of M. tibialis cranialis appears after M. fiburalis longus is removed. The muscle has two heads: caput tibiale and caput femorale. The caput tibiale, tibial head, is superficial to the femoral branch and arises mainly from the crista cnemialis lateralis of tibiotarsus (Fig. 10- point 61) and partly from the anterior surface of the cartilaginous compartment of patellar ligament. The belly of deeper caput femorale, femoral head, passes cranially to the space between the crista cnemialis lateralis of tibiotarsus and the anterior corner of the head of fibula. The caput femorale arises by a stout tendon from the notch on the anterodistal end of the external femoral condyle (Fovea tendineus M. tibialis cranialis: point 39 of Fig. 10). The belly tapers to a large tendon at the distal half of tibiotarsus. The tendon is held close to the anterior surface of the tibiotarsus by a strong ligament (Ligamentum transversum) near the distal end of the bone. The tendon crosses the anterior edge of the tibiotarsal-tarsometatarsal joint and inserts to the bifurcated tubercle on the anterior surface of tarsometatarsus (Tuberositas M. tibialis cranialis on the proximal end of the bone: point 86 of Fig. 10). Between the bifurcated insertions, a blood vessel appears.

3. M. fibularis brevis

短腓骨筋

(M. peroneus brevis, Peroneus profundus)

M. fib. brev., or T3 in figures.

M. fibularis brevis is a relatively weakly developed muscle. The muscle arises from the distal half of the anterior surface of fibula (Fig. 10- point 62), about the position distal to the insertion of M. iliofibularis. The belly is small at its origin but increases in size distally before tapering to a stout tendon. The tendon inserts on the lateral surface of the proximal end of the tarsometatarsus just plantar to the course of the tendon of M. fibularis longus (Fig. 10- point 81).

4. M. fibularis longus

長腓骨筋

(M. peroneus longus, Peroneus superficialis)

M. fib. long., or T4 in figures.

M. fibularis longus is a superficial developed muscle on the anterolateral aspect of the crus. The main origin is the lateral surface of fibula, at its portion of the level of crista fibularis of tibiotarsus (Fig. 10- point 57a), but the belly extends to the knee joint and partly arises from the surface of the cartilaginous compartment of patellar ligament, cranial margin of crista cnemialis cranialis, and tip of crista cnemialis lateralis (Fig. 10- point 57b). The muscle tapers to a large tendon. The tendon is anchored to the lateral surface of the tibial cartilage by a large band of tendinous fibers. The main tendon crosses the lateral surface of the tibiotarsus -tarsometatarsus joint and fuses with the tendon of M. flexor perforatus digiti III (the accessory part: T9) at the planter point distal to the proximal end of tarsometatarsus.

5. M. flexor perforans et perforatus digiti III

第三趾貫通および有孔屈筋

M. flex. p. et p. dig. III, or T5 in figures.

This muscle and the posterior next M. flexor perforans et perforatus digiti II (T6) are the superficial muscles on the lateral surface of the crus, appear at the space between M. fibularis longus in anterior and M. gastrocnemius pars lateralis in posterior. Together with the most superficial M. gastrocnemius pars lateralis, these two muscles conceal the insertion of M. iliofibularis and the biceps loop from the lateral view. M. flexor perforans et perforatus digiti III has two origins: 1) the anterocranial head which is superficial to the aponeurosis of M. iliotibialis lateralis arises by an aponeurosis from patellar ligament, and 2) the posterior head which is deep to the aponeurosis of M. iliotibialis lateralis + M. femotibialis lateralis arises by tendinous fibers from the anterior-corner tubercle of the proximal end of fibula (Fig. 10- point 51). The muscle tapers to a relatively strong tendon in its distal portion. The tendon passes through the posterior surface of the tibial cartilage, in which the tendon locates the middle of three tendons, medial to the tendon of M. flexor perforatus digiti IV (T8) and lateral to the tendon of M. flexor perforans et perforatus digiti II (T6). These three tendons form the first (posterior most, first of three) line of tendons in tibial cartilage. The tendons perform complicated branching and stoppings in the basal surface of the foot skeleton. Note the twist of the tendons of M. flexor perforans et perforatus digiti III (T5) and the “A” tendon (fused T9 and T10) at the plantar aspect of tarsometatarsus (Fig. 7- left).

6. M. flexor perforans et perforatus digiti II

第二趾貫通および有孔屈筋

M. flex. p. et p. dig. II, or T6 in figures.

This muscle and M. flexor perforans et perforatus digiti III contact tightly and the bellies are almost fused in proximal part. The muscle arises by tendinous fibers from the tubercle on the lateral portion of caudal surface of the distal end of femur (Fig.

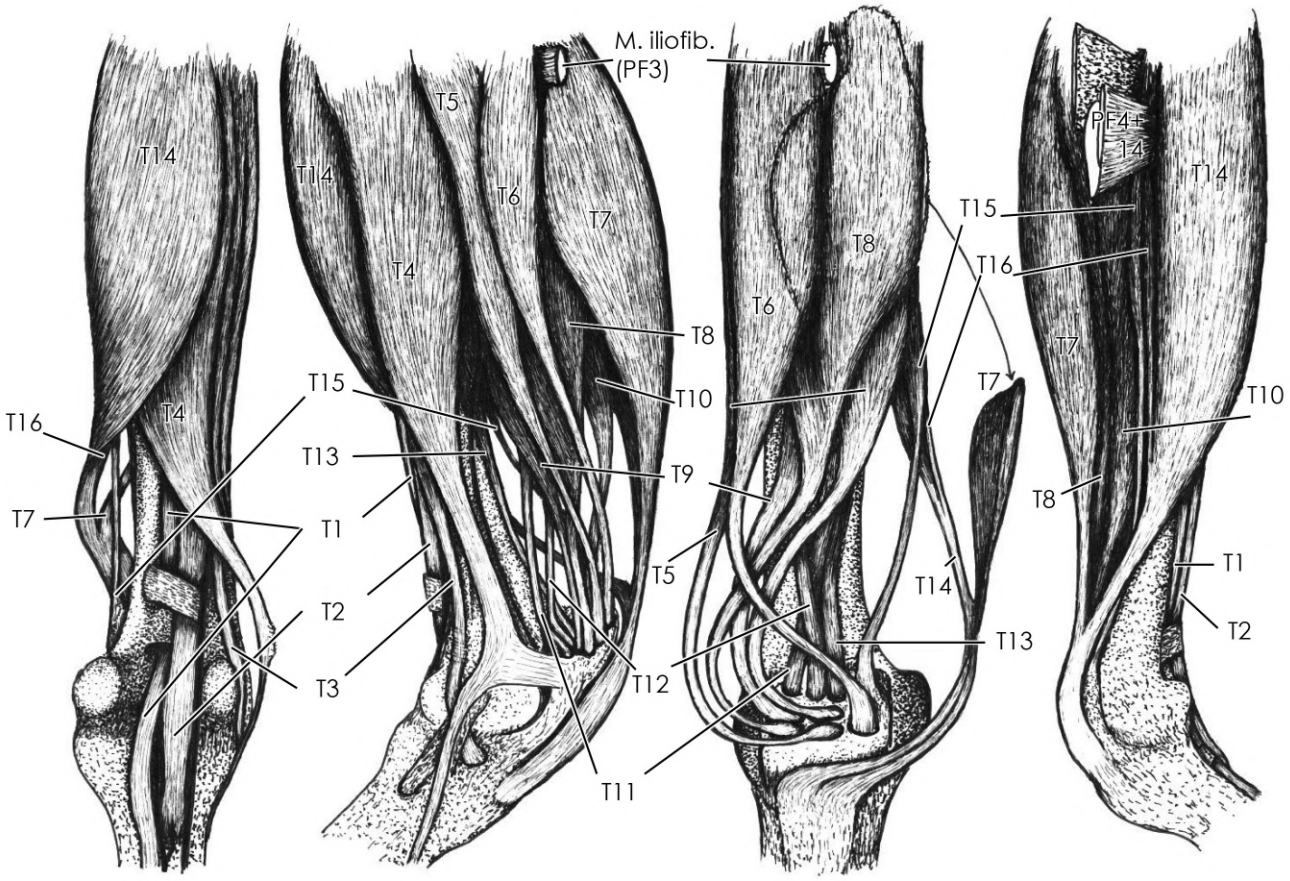

Figure 5. The positionings of 16 terminations crus muscles (T1-T16) of Whooper Swan *Cygnus cygnus*. Showing the left crus. The anterior, lateral, posterior, and medial views from left to right. See Table 1 for muscle name abbreviations. Not a measured drawing.

10- point 36), just proximal to the tubercle for the origin of the posterior head of M. flexor perforans et perforatus digiti III and distal to the long tubercle for the origin of M. gastrocnemius pars lateralis. The belly of M. flexor perforans et perforatus digiti II tapers to a flat tendon and passes through the most medial position of the "first line" of tibial cartilage. The tendon then passes through the bony canal (Fig. 10- point 92) in the hypotarsus, in which the sulcus just lateral next to the crista medialis hypotarsi. The tendon finally inserts on the lateral corner of the base of the second phalanx of digit II.

7. M. gastrocnemius pars lateralis

腓腹筋外側部

(Pars externa)

M. gastric. lat., or T7 in figures.

M. gastrocnemius pars lateralis is a large muscle superficial on the lateral back of the crus and is one of the two large belly of M. gastrocnemius. The belly of M. gastrocnemius pars lateralis extends nearly half of the crus. The distal tendon forms the lateral part of the Tendo Achillis, of which the medial part is formed by the tendon of m. gastrocnemius pars medialis (T14) (+ pars intermedia: T16, see below). The belly of M. gastrocnemius pars lateralis contacts tightly with the belly of anterior next M. flexor perforans et perforates digit II (T6). M. gastrocnemius pars lateralis turns to a strong tendon for the origin and has the origin on the 12 mm long tubercle (Tuberculum M. gastric. lat., the point 35 of Fig. 10) located on the posterolaetral surface of femur just proximal to the femoral condylus lateralis.

8. M. flexor perforatus digiti IV

第四趾有孔屈筋

M. flex. perf. dig. IV, or T8 in figures.

The belly of this muscle lies deep to Mm. flexores perforantes et perforati digiti II et III (T5 and T6) and appears in the lateral view at the back of M. iliofibularis after T5, T6, T7 muscles are removed. The tendon, however, passes anterior to the tendons of M. flexores perforantes et perforati digiti II et III and appears to the most superficial (lateral) position of the "first line" of tibial cartilage (Fig. 4). The muscle arises by strong and short tendon from the tubercle located on the medial portion of the posterior surface of femur just proximal to the femoral condylus medialis (Fig. 10- point 47). The arising tendon is in common with the main head of M. flexor perforatus digiti III (T10) and M. flexor perforatus digiti II (T12). After appeared in the superficial position of the "first line", the tendon of M. flexor perforatus digiti IV passes under digit IV. The tendon trifurcates at the position of trochlea metatarsi IV to "l", "m" and "d" branches of this study, and finally ("d" branch) inserts on the base of the third phalanx of digit IV.

9. M. flexor perforatus digiti III – the accessory

第三趾有孔屈筋（その付属部：正式名称なし）

M. flex. perf. dig. III acs., or T9 in figures.

M. flexor perforatus digiti III has two parts, though official names are not given to classify them. The main and accessory muscles fuse to the single, quite wide tendon at the back of ankle, the "A" tendon in this study (Figs. 6 and 7). The accessory muscle (T9) arises as the continuation of the tendon of M. ambiens (PF18). T9 passes the lateral surface of fibula at the position just proximal to the insertion of M. iliofibularis (PF3) with leaving a clear oblique sulcus on the lateral surface of fibula, and fans out to an independent belly at the proximal to middle crus. The boundary between the ambiens tendon and T9

is not recognizable. The muscle tapers to a flat tendon (again) at the distal portion of tibiotarsus, and then fuses with the tendon of the main belly (T10), which locates medially, at a short distance proximal to the tibial cartilage. The wide tendon formed by the main (medial) and accessory (lateral) ones of M. flexor perforatus digiti III, named "A" tendon in this study, is the "second line" of tibial cartilage and acts as the "catching sheet" for the posterior ("first line") two tendons, M. flexor perforans et perforatus digiti III (T5) in medial and M. flexor perforatus digiti IV (T8) in lateral. Within the "A" tendon, the part of the T9 tendon accompanies with T8 to pass tibial cartilage and hypotarsus. The "A" tendon passes over the shallow sulcuses on the lateral portion of hypotarsus (points 93 and 94 of Fig. 10). At the point just distal to hypotarsus, the tendon of M. fibularis longus comes to fuse on "A" tendon, especially on the part of T9 tendon. While passing the plantar tarsometatarsus, the "A" tendon turns to medial and posteriorly to the tendon of M. flexor perforans et perforatus digiti III (T5), and then goes to the planter side of digit III as the superficial layer. The "A" tendon inserts on the base of the second phalanx of digit III.

10. M. flexor perforatus digiti III – the main

第三趾有孔屈筋（その主部）

M. flex. perf. dig. III main, or T10 in figures.

As noted above, M. flexor perforatus digiti III has two parts: the main and the accessory. The main M. flexor perforatus digiti III (T10) is visible on the inside of the thigh of skinned bird, but

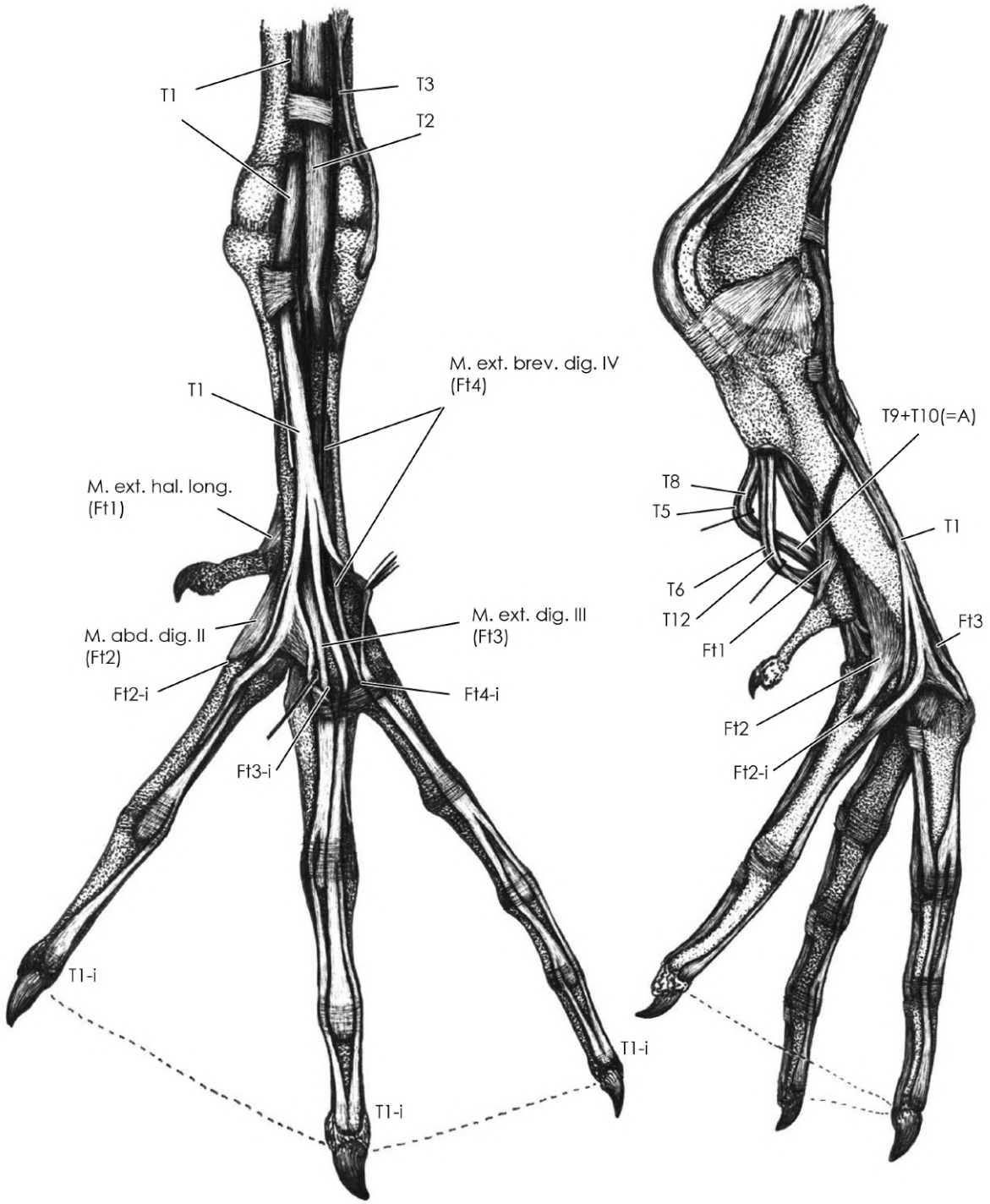

Figure 6. The foot extensors of the Whooper Swan *Cygnus cygnus*. The anterior (left) and medial (right) views of left foot. See Table 1 for the muscle name abbreviations. Abbreviations i means insertion. Not a measured drawing.

in the sense of anatomy, the bellies of both muscles locate in the layer deep to M. flexor perforatus digiti IV (T8), where is the second deepest superficial to the deepest M. flexor digitorum longus (T13) and M. flexor perforates digit II (T12). The main M. flexor perforatus digiti III arises as tendinous fibers from the medial part of the intercondyloid region of the femur in common with M. flexor perforatus digiti II (T12) and M. flexor perforatus digiti IV (T8) (Fig. 10- point 47). In the mid-tibiotarsus region, the bellies of main and accessory muscles of M. flexor perforatus digiti III and M. flexor hallucis longus (T11) in between perform as one fleshy sheet. Distally as the tendon of M. flexor hallucis longus passes anterior to the tendons of main and accessory muscles of M. flexor perforatus digiti III, two tendons run side-by-side in the ankle region, and fuse at a short distance proximal to the tibial cartilage. This is the "A" tendon, which have been noted above.

11. M. flexor hallucis longus

長母趾屈筋

M. flex hal. long., or T11 in figures.

The belly of M. flexor hallucis longus locates in between the main (T10) and accessory (T9) muscles of M. flexor perforatus digiti III and these three bellies form a layer in deep mid-crus. The belly of M. flexor perforatus digiti II (T12) in that position locates deeper to the layer of T9-T11-T10. As M. flexor hallucis longus turns to tendon, the tendon shifts anteriorly (deeper) to pass parallelly and lateral to the tendon of M. flexor perforates

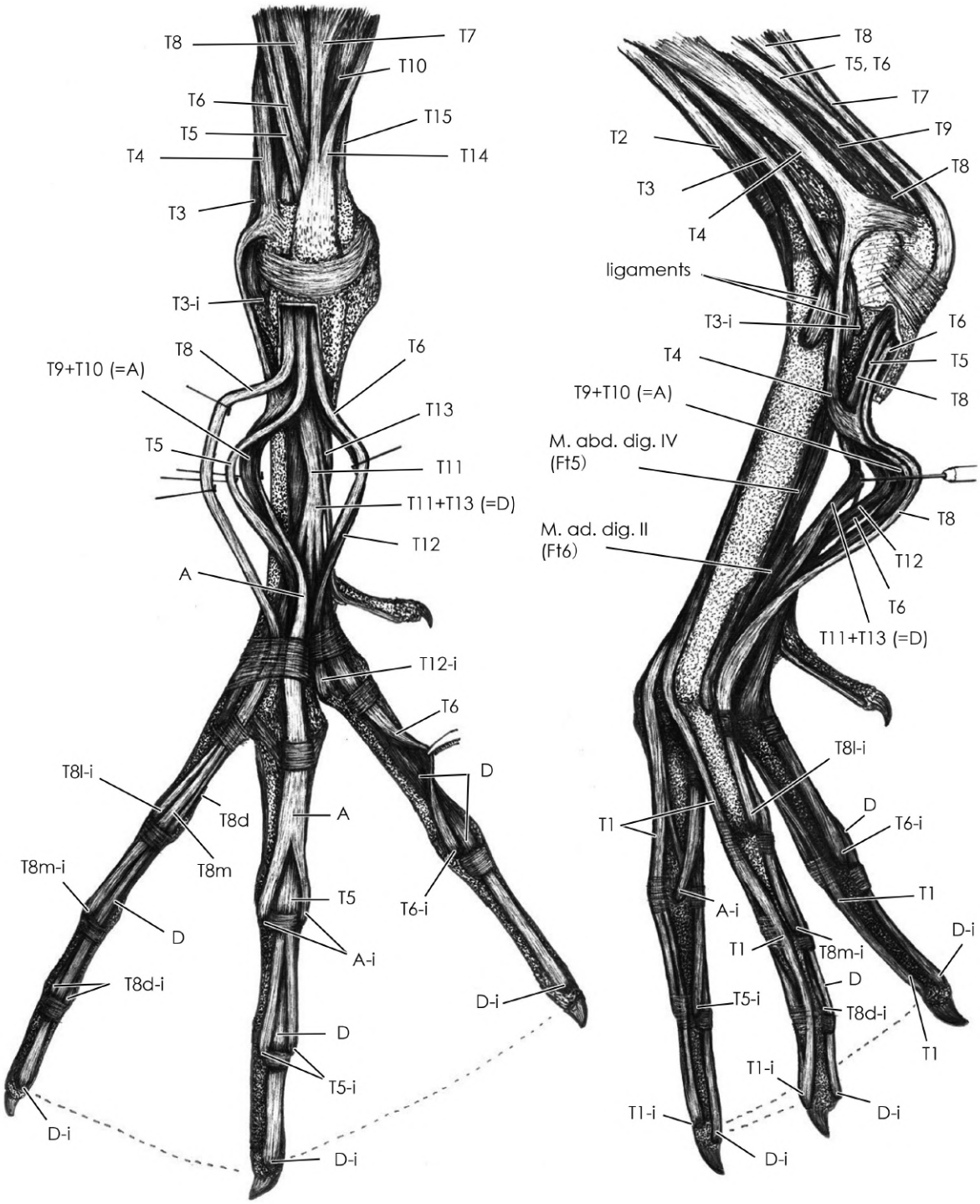

Figure 7. The foot flexors of the Whooper Swan *Cygnus cygnus*. The posterior (plantar) (left) and lateral (right) views of left foot. See Table 1 for the muscle name abbreviations. Abbreviations i means insertion. Not a measured drawing.

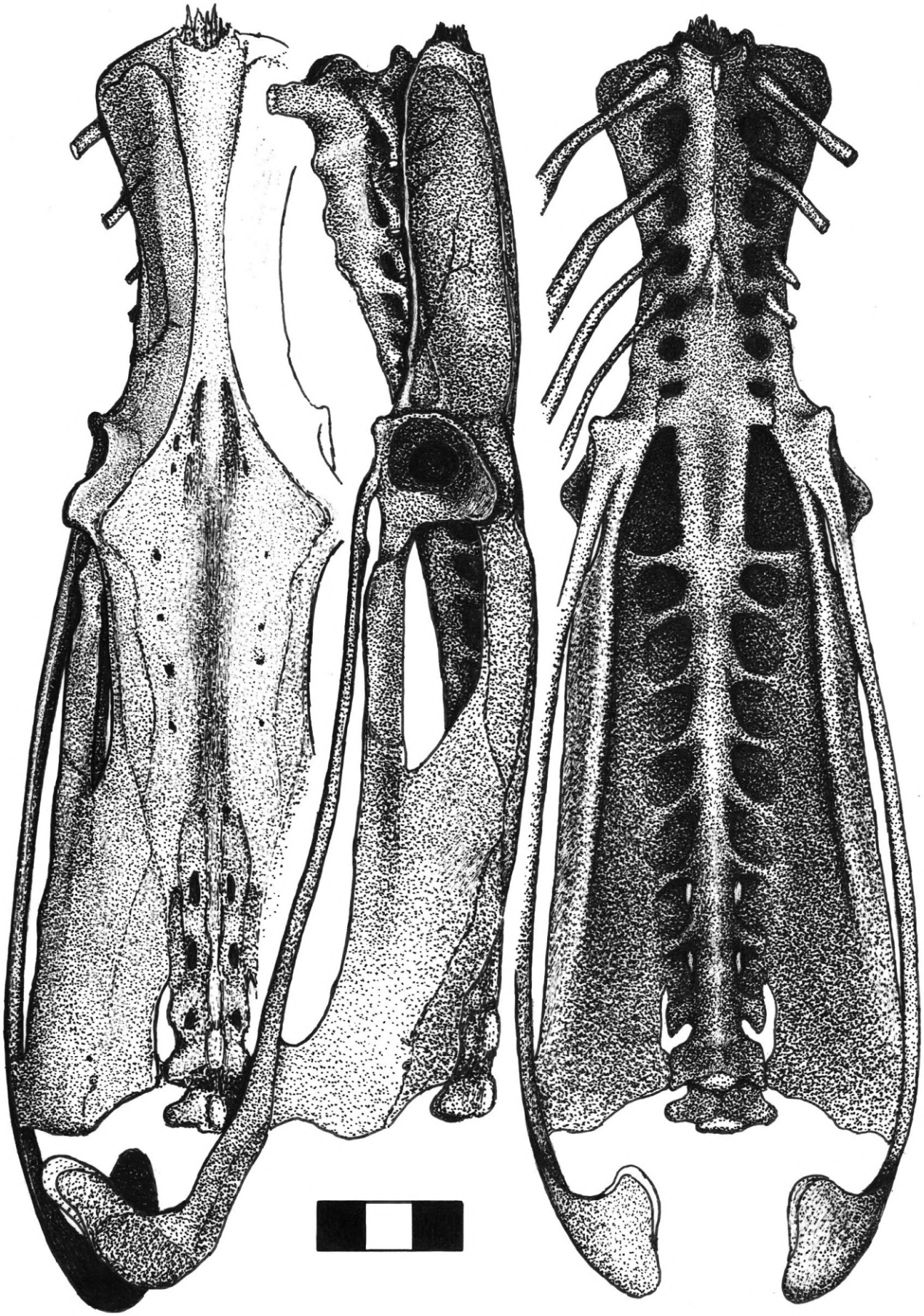

Figure 8. The measured drawing of the pelvis of the Whooper Swan *Cygnus cygnus*. Cranial to the top of figure, and from left to right, three views are, dorsal, lateral (left), and ventral views, respectively. Scale bar is 3 cm in total.

digiti II. The tendon then passes the "third (deepest, most anterior) line" of tibial cartilage in which the lateral position of the three tendons, passes the lateral canal of hypotarsus, and appears on plantar surface of tarsometatarsus. At mid-tarsometatarsus position, this tendon fuses with the tendon of M. flexor digitorum longus (T13), but before they fuse, a small tendon branches out to be the flexor of hallux. The fusion of the tendons of M. flexor hallucis longus and M. flexor digitorum longus is so called the overlapping type: the latter slides into the space between the bone and former tendon and fuses on the deeper surface of it. The fused tendon is called "D" tendon in this study (Fig. 7). The "D" tendon includes a small sesamoid bone in it. The "D" tendon trifurcates at distal plantar tarsometatarsus, and branched tendons turn toward digits II, II and IV, and pass the deepest position of each digits. The "D" branches all insert on the base of the terminal phalanx (phalanx ungualis) of each digit.

12. M. flexor perforatus digiti II

第二趾有孔屈筋

M. flex. perf. dig. II, or T12 in figures.

The belly of M. flexor perforatus digiti II is one of the deepest one only superficial to M. flexor digitorum longus (T13). The origin, arises as tendinous fibers from the medial part of the intercondyloid region of the femur (Fig. 10- point 47), is in common with the main M. flexor perforatus digiti III (T10) and M. flexor perforatus digiti IV (T8). Among the three inserting muscles, M. flexor perforates digiti II locates anterior (distal for femur), the main M. flexor perforatus digiti III is in the middle, and M. flexor perforatus digiti IV is lateral (proximal for femur) position, though they are unidentifiable on the femoral tuberosity. The tendon of M. flexor perforates digiti II passes the "third (deepest, most anterior) line" of tibial cartilage, the middle position of the three tendons (Fig. 4). The tendon then passes the middle canal of hypotarsus (Fig. 10- point 90), shifts medial and becomes to be linked with the superficial tendon of M. flexor perforans et perforates digiti II (T6) soon after passed the canal, and while passing the plantar tarsometatarsus twists over the T6 tendon, and finally inserts on the lateral corner of the base of the proximal phalanx of digiti II.

13. M. flexor digitorum longus

長趾屈筋

M. flex. dig. long., or T13 in figures.

M. flexor digitorum longus is the deepest muscle on the posterior tibiotarsus. The muscle arises widely by fleshy fibers from the posteromedial surface of fibula and the proximolateral portion of posterior surface of tibiotarsus (Fig. 10- point 75). The tendon passes tibial cartilage at the medial position of three "third line" tendons, where is medial next of the insertion of M. plantaris (T15). The tendon then passes the medial canal of hypotarsus (Fig. 10- point 89) and appears on the medial position of plantar tarsometatarsus. The tendon fuses to the tendon of M. flexor hallucis longus (T11). The performance of fusion and fused "D" tendon have noted in the section of M. flexor hallucis longus.

14. M. gastrocnemius pars medialis

腓腹筋内側部

(Pars interna)

M. gastric. med., or T14 in figures.

The large superficial muscle locates on the anterior portion of the medial surface of crus. The anterior margin of its belly shares the position of anterior most margin of the crus with lateral next M. fibularis longus. After the small tendon of M. gastric. pars intermedia (T16) fused on it, the tendon of M. gastrocnemius pars medialis forms the main (medial) part of Tendo Achillis, together with M. gastrocnemius pars lateralis. The origin is weakly anchored on the medial surface (facies gastrocnemialis) of crista cnemialis cranialis of tibiotarsus but the belly passes over the crest and the muscle arises from the surface of the cartilaginous compartment of patellar ligament (Fig. 3).

15. M. plantaris

足底筋

M. plant., or T15 in figures.

M. plantaris is a very small muscle locates in the posteromedial portion of crus, being adjacent to the pars intermedia of M. gastrocnemius (T16). M. plantaris arises by fleshy fibers from the proximomedial surface of the shaft of tibiotarsus, just below the facies articularis medialis of the proximal end of bone (Fig. 10- point 70). The origin is depressed clearly on the bone. The muscle tapers to a thin tendon, and then inserts on the proximomedial corner of tibial cartilage.

16. M. gastrocnemius pars intermedia

腓腹筋中間部

(Pars media)

M. gastric. intermed., or T16 in figures.

M. gastrocnemius pars intermedia is a very small, almost vestigial, muscle. Locates posterior to the M. gastric. pars medialis with the separation by the insertion of M. flexor cruris lateralis pars pelvica (PF4) + flexor cruris medialis (PF14). The muscle arises by tendinous fibers from the posterior surface of the internal femoral condyle (Fig. 10- point 50). The small belly of T16 turns to a flat tendon and the tendon fuses on the posterior margin of the tendon of M. gastric. pars medialis (T14) at the point of belly-tendon transition of pars medialis.

1 deep muscle in crus doesn't cross knee/ankle joints (Figs. 2 and 4)

1. M. popliteus

膝窩筋

M. pop. in figures.

M. popliteus is a short and wide fleshy muscle appears on the posterior surface of proximal crus bones. The muscle arises from the posteromedial surface of the proximal end of fibula (Fig. 10- point 73). The belly passes medially and inserts on the posterior surface of the proximal shaft of tibiotarsus. The insertion (Fig. 10- point 74) leaves the impression on bone, which is roughly circular and about 10 mm diameter.

6 muscles arising from tarsometatarsus (Ft1-Ft6) (Figs. 6 and 7)

1. M. extensor hallucis longus

長母趾伸筋

M. ext. hal. long., or Ft1 in figures.

A small muscle arises from the crista plantares medialis and inserts on the dorsal lip of the base of proximal phalange.

2. M. abductor digiti II

第二趾外転筋

M. abd. dig. II, or Ft2 in figures.

A short but strong muscle arises from the medial surface of the distal portion, distal to the base of hallux, of tarsometatarsus (Fig. 10- point 98). Inserts by tendinous fibers on the dorsomedial corner of the base of the proximal phalanx of digit II.

3. M. extensor proprius digiti III (sense of George and Berger)

第三趾固有伸筋

M. ext. dig. III, or Ft3 in figures.

A short muscle arises by fleshy fibers from the area proximal to the trochlea for digit III on the anterior surface of distal tarsometatarsus (Fig. 10- point 07). The belly tapers to dense tendon and inserts on mid-dorsal lip of the base of the proximal phalanx of digit III.

4. M. extensor brevis digiti IV

第四趾短伸筋

M. ext. brav. dig. IV, or Ft4 in figures.

A long thin muscle arises widely by fleshy fibers from the anterior surface of tarsometatarsus (Fig. 10- point 96). The lateral margins are limited by ligament membrane wrapping foot extensors, and the proximal termination is just distal to the

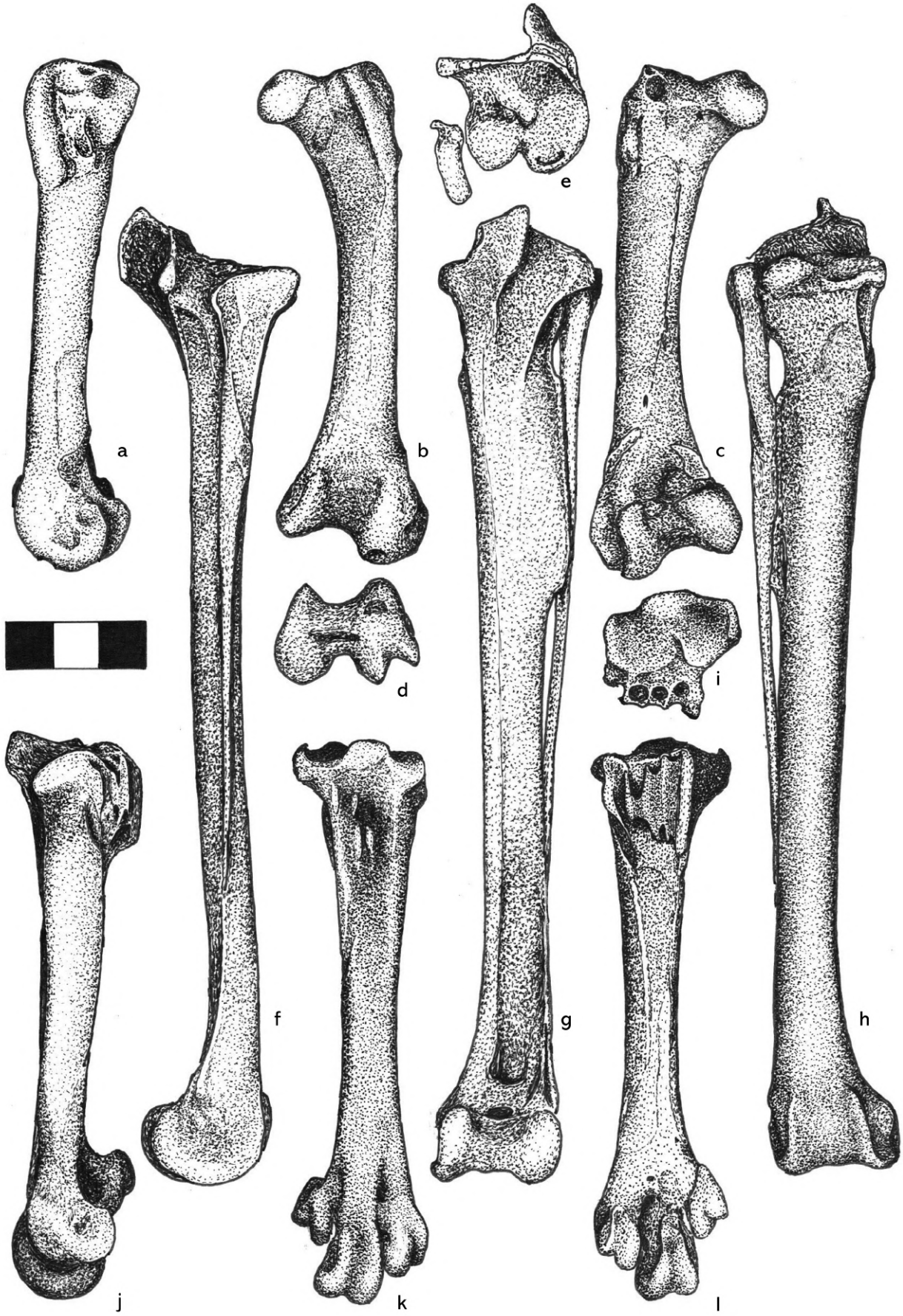

Figure 9. The measured drawing of the femur, tibiotarsus, fibula, and tarsometatarsus of Whooper Swan *Cygnus cygnus*. Cranial to the top of figure, if not oriented particularly. a-d: the lateral, anterior, posterior, and distal views of left femur. e-h: the proximal, lateral, anterior, and posterior views of articulated left tibiotarsus and fibula. i-l: the proximal, lateral, anterior, and posterior views of left tarsometatarsus. d, e, and i are anterior to the top of figure. Scale bar is 3 cm in total.

Table 2. The explanation of the osteological 106 points of Figure 10.

1	origin of PF18	54	sulcus for T9
2	origin of PF17	55	impression of ligament (to 38)
3	attachment of abdomen wall	56	insertion of PF3
4	origin of M. pubocaud. int.	57	main (a) and proximal (b) origins of T4
5	origin of M. pubocaud. ext.	58	tubercle of ligament (to 84)
6	origin of M. lev. caud. rectr.	59	sulcus for T3
7	origin of M. dep. caud.	60	insertion of PF11
8	origin of PF1	61	origin of caput tibiale of T2
9	origin of PF2	62	origin of T3
10	origin of PF5	63	impressions of Lig. transversum
11	origin of PF7	64	canal for T1
12	origin of PF8	65	attachment of the support T3
13	origin of PF6	66	impression of Lig. intercondylare tibiometatarsale (to 79)
14	impression of Lig. capitis. (to 41)	67	impression of Lig. tibiofibulae craniale
15	sulcus for inserting PF17	68	tubercle of Lig. cruciati cranialis (to 40)
16	origin of PF3	69	impression of Lig. cruciati caudale (to 49)
17	origin of PF4	70	origin of T15
18	origin of PF12	71	tubercle of ligament (to 45)
19	origin of PF14	72	insertion of PF4+14
20	origin of PF15	73	origin of M. pop
21	origin of PF16	74	insertion of M. pop
22	origin of M. trans. cloac.	75	origin of T13
23	origin of M. lev. caud. vert.	76	tubercle of ligament (to 95)
24	origin of M. lat. caud.	77	tubercle of ligament (to 106)
25	depression for aorta	78	sulcus for tibial cartilage
26	insertion of PF5	79	tubercle of Lig. intercondylare tibiometatarsale (to 66)
27	insertion of PF7	80	main insertion of T7+14(+16)
28	slider for PF5+7	81	insertion of T3
29	impression of medial anchor of PF6	82	impression of a blood vessel
30	insertion of PF17	83	sulcus for T4
31	insertion of PF16	84	tubercul for ligament (to 58)
32	insertion of PF6	85	impressions of Retinaculum extensorium tarsometatarsi
33	origin of PF10	86	insertion of T2
34	origin of PF9	87	attachment of anterior sheath
35	origin of T7	88	impression of a blood vessel
36	origin of T6	89	canal of T13
37	origin of T11	90	canal of T12
38	impression of ligament (to 55)	91	canal of T11
39	origin of caput femorale of T2	92	sulcus for T6
40	impression of Lig. cruciati cranialis (to 68)	93	sulcus for T10
41	impression of Lig. capitis. (to 14)	94	sulcus for T9
42	insertion of PF8	95	tubercul for ligament (to 76)
43	origin of PF11	96	origin of Ft4
44	line of mid-PF10	97	origin of Ft3
45	impression of ligament (to 71)	98	origin of Ft2
46	insertion of PF12+13	99	foramen for a blood vessel
47	insertion of PF15	100	origin of Ft5
48	origin of T8+10+12	101	origin of Ft6
49	impression of Lig. cruciati caudale (to 69)	102	attachment of posterior sheath
50	origin of T16	103	attachment of metatarsus I
51	main origin of T5	104	impression of the ligament wrapping the base of digs. III, IV
52	attachment for patellar ligament	105	impression of the ligament connecting to tibial cartilage
53	origin of T1	106	tubercle for ligament (to 77)

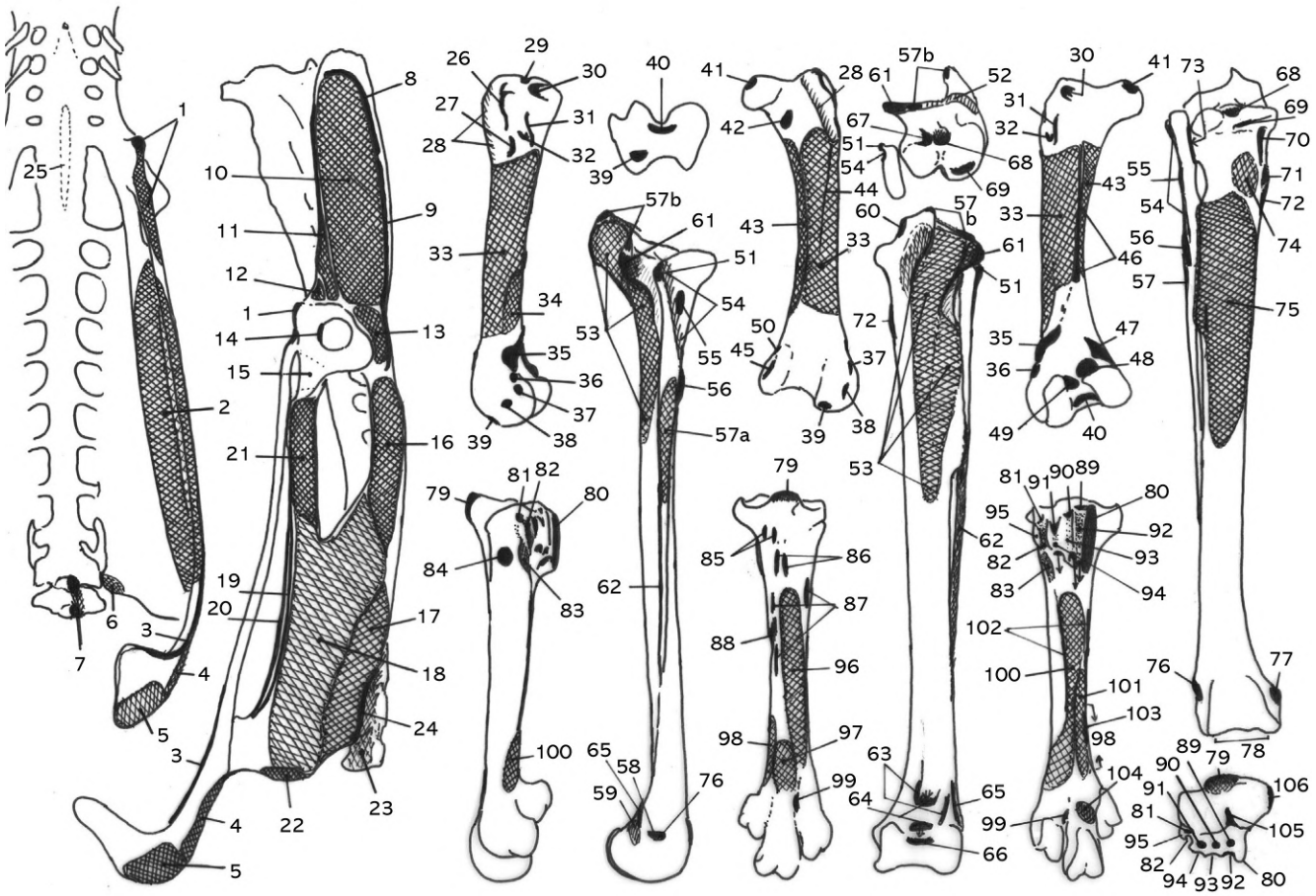

Figure 10. The guide to the morphology of pelvis, femur, tibiotarsus, fibula, and tarsometatarsus of Whooper Swan *Cygnus cygnus*. The explanation of 106 points indicated here is listed in Table 2.

insertion of M. tibialis cranialis (T2). Passes by the foramen vasculare distale and inserts on the medial surface of the base of the proximal phalanx of digit IV.

5. M. abductor digiti IV

第四趾外転筋

M. abd. dig. IV, or Ft5 in figures.

A long thin muscle arises widely by fleshy fibers from the posterior surface of tarsometatarsus, in the space between crista plantares medialis et lateralis and the proximal termination is the base of hypotarsus (Fig. 10- point 100). The tendon appears on the lateral surface of distal end of tarsometatarsus and inserts on the ventrolateral corner of the base of the proximal phalanx of digit IV.

6. M. adductor digiti II

第二趾内転筋

M. ad. dig. II, or Ft6 in figures.

The medial shorter muscle on the plantar surface of tarsometatarsus. The muscle is short relative to the lateral next M. abductor digiti IV, but the proximal termination is at the middle of bone length, and then the muscle is longer than the antagonist M. abductor digiti II. Arises from the space between M. abductor digiti IV in lateral and the medial wall of flexor sheath (Fig. 10- point 101) and inserts on the lateral surface of the base of the proximal phalanx of digit II.

Measurements of bones at the points defied by Von den Driesch (1976)

Pelvis

GL, greatest length without pubis, 234.5 mm
LV, length along the fused vertebrae, 217.0 mm
CB, cranial breadth, 47.4 mm
SB, smallest breadth of the Partes glutaeae, 30.8 mm
AA, breadth between the borders of acetabula, 45.4 mm
DiA, diameter of one acetabulum, 14.4 mm
BA, breadth across the two antitrochanter, 64.4 mm

Femur

GL, greatest length, 110.0 mm
Lm, medial length, 102.0 mm
Bp, breadth of the proximal end, 29.4 mm
Dp, depth of the proximal end, 20.2 mm
SC, smallest breadth of the corpus, 13.0 mm
Bd, breadth of the distal end, 30.6 mm
Dd, depth of the distal end, 24.0 mm

Tibiotarsus

GL, greatest length, 211.2 mm
La, axial length, 200.1 mm
Bp, breadth of the proximal end, 23.2 mm
Dip, diagonal of the proximal end, 34.3 mm
SC, smallest breadth of the corpus, 12.2 mm

Bd, breadth of the distal end, 26.1 mm
Dd, depth of the distal end, 25.5 mm

Tarsometatarsus

GL, greatest length, 123.2 mm
Bp, breadth of the proximal end, 27.4 mm
SC, smallest breadth of the corpus, 11.5 mm
Bd, breadth of the distal end, 26.7 mm

REMARK

The authors did not find M. lunbriealis in the process of dissection. We believe M. lunbriealis is absent in *Cygnus cygnus* like many avian species. However, because this study depends on only one individual, the reason can be the individual differences or the problem of preservation state of the specimen. Then it should be the future subject whether this muscle is absent in *Cygnus* or not.

ACKNOWLEDGEMENTS

I wish to thank anonymous referee for his/her kind advices. We are grateful to Dr. HASEGAWA Yoshikazu of the Gunma Museum of Natural History for helpful discussions and comments on the manuscript. We also thank the staffs of the Gunma Museum of Natural History for their assistance. This work was supported by ITO Hiroe and YOSHIDA Masashi of Graduate School of Science, Kyoto University.

REFERENCES

Baumel, J. J.（1979）: Osteologia. *In* Baumel, J. J. et al.（eds.）Nomina anatomica avium. An annotated anatomical dictionary of birds, Academic Press, London, p.53-121.

Berge, J. C. V.（1979）: Myologia. *In* Baumel, J. J. et al.（eds.）Nomina anatomica avium. An annotated anatomical dictionary of birds, Academic Press, London, p.175-219.

Clifton, G.T, Carr, J. A. and Biewener, A. A.（2018）: Comparative hindlimb myology of foot-propelled swimming birds. *Journal of Anatomy*, 232：105-123.

George, J. C. and Berger, A. J.（1966）: Avian Myology. Academic Press, New York, 500pp.

Ghetie V., Chitescu St., Cotofan V. and Hillebrand A.（1976）: Anatomical atlas of domestic birds, Editura Academiei Republicii Socialiste Romania, Bucuresti, 294pp.

Japanese Association of Veterinary Anatomists（eds., 1998）: Nomina anatomica avium Japonicum. Gakusosha., Co. Ltd., Tokyo, p. 87-89.

Matsuoka, H. and Hasegawa, Y.（2007）: Myology and osteology of the Whooper Swan *Cygnus cygnus*（Aves: Anatidae）Part 1. Muscle attached to the sternum, coracoid, clavicle, scapula and humerus. *Bulletin of Gunma Museum of Natural History*,（11）: 7-14.

Matsuoka, H., Kurosu, H., Inglis, M. P., Kitagawa, H., Kusuhashi, N., Hasegawa, Y.（2008）: Myology and osteology of the whooper swan *Cygnus cygnus*（Aves: Anatidae）Part 2. Muscles of the jaws, tongue and anteriormost neck. *Bulletin of Gunma Museum of Natural History*,（12）: 1-14.

Von den Driesch, A.（1976）: A Guide to the Measurement of Animal Bones from Archaeological Sites. Peabody Museum Bulletin,（1）. Peabody Museum of Archaeology and Ethnology, Harvard University, Cambridge, Massachusetts, U.S.A., 137pp.

Yasuda, M.（2002）: The anatomical atlas of gallus, University Tokyo Press, Tokyo, 445pp.

オオハクチョウの筋学と骨学　その3：
骨盤・大腿骨・脛足根骨・足根中足骨・趾骨に付着する筋

松岡廣繁[1]・瀬岡理子[1]

[1]京都大学大学院理学研究科地質学鉱物学教室：〒606-8502 京都市左京区北白川追分町

要旨：本論文はMatsuoka and Hasegawa（2007）が開始したオオハクチョウ（カモ科ハクチョウ族：学名 *Cygnus cygnus*）の筋学と骨学の記載の第3報である。群馬県立自然史博物館に所蔵されている液浸標本（GMNH-VA-04-02）を用い，同種の下肢帯及び尾部の筋群について，その起始・停止を明示しながら図示，記載した．合計48の筋を同定した．またそれらを骨盤主部および大腿骨の周囲にあるもの18筋，骨盤最後部から起始し尾部の運動を司るもの7筋，下腿に筋腹があり足首を腱で通過する16筋，下腿最深部にあり膝関節も足根間関節も通過しない1筋，足根中足骨に起始して指の運動に寄与する6筋に分類した．虫様筋は認められなかった．

キーワード：カモ科，オオハクチョウ，*Cygnus cygnus*，筋学，骨学，下肢